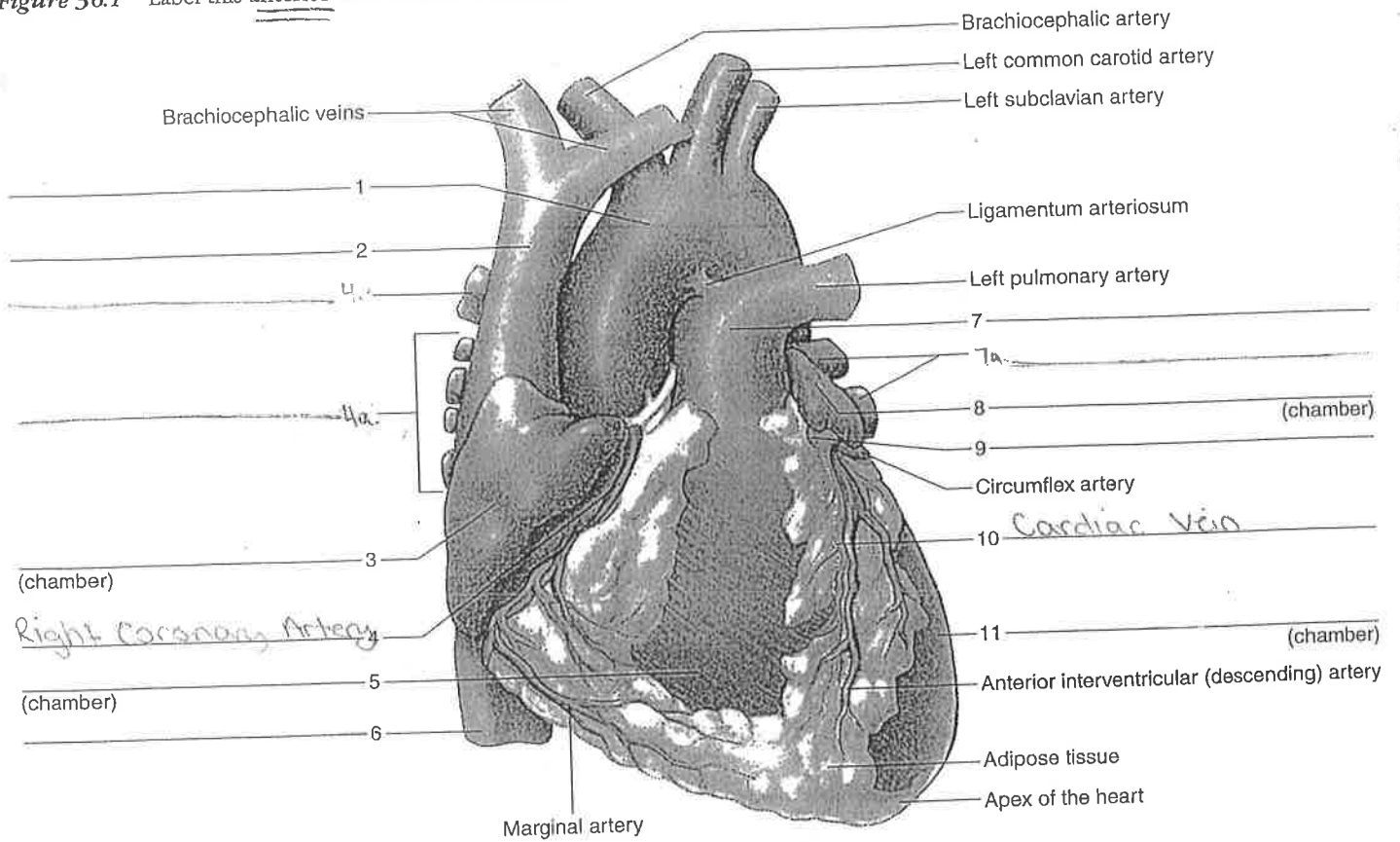


* Anterior *

Figure 36.1 Label this anterior view of the human heart.



* Posterior *

Figure 36.2 Label this posterior view of the human heart.

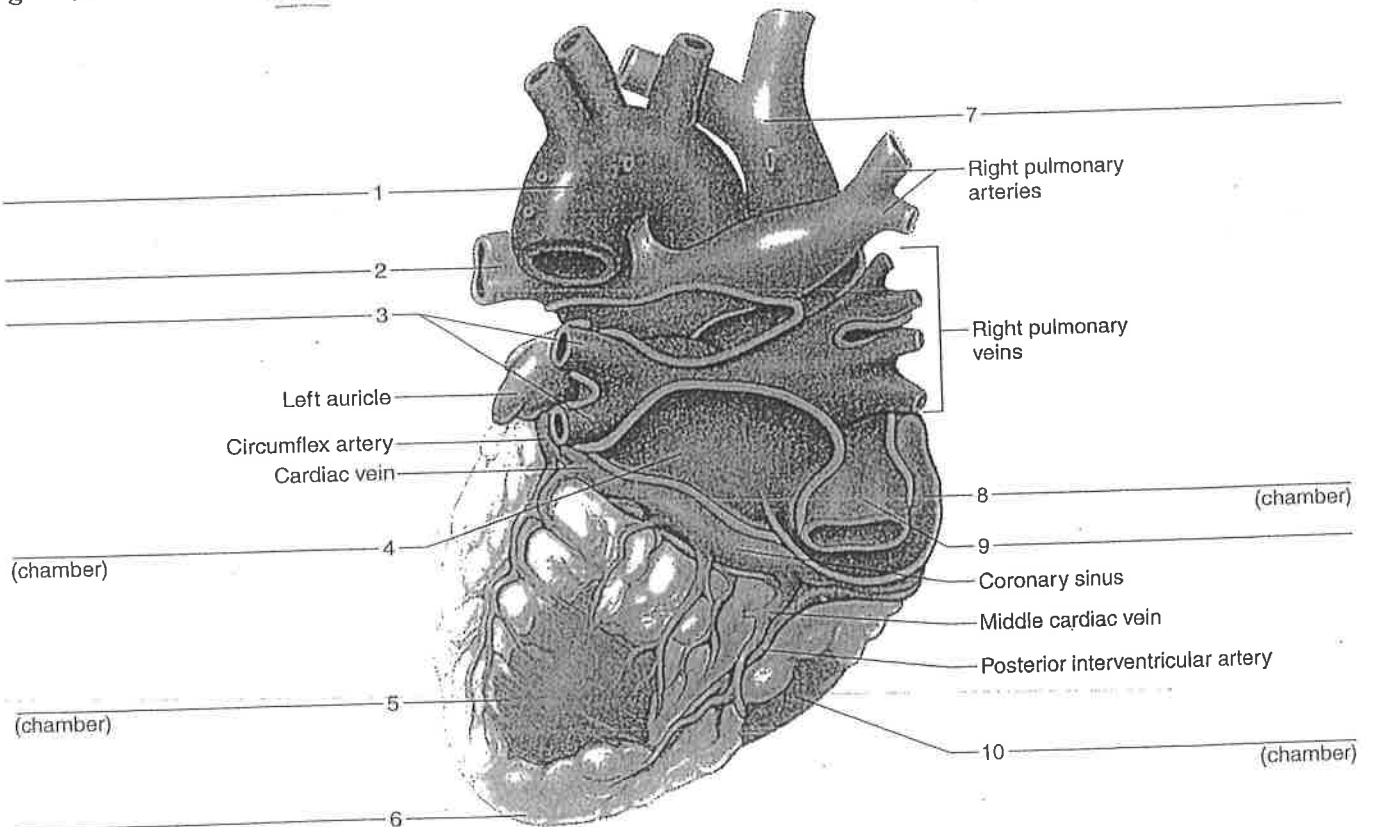


Figure 36.3 Label this coronal section of the human heart. The arrows indicate the direction of blood flow.

