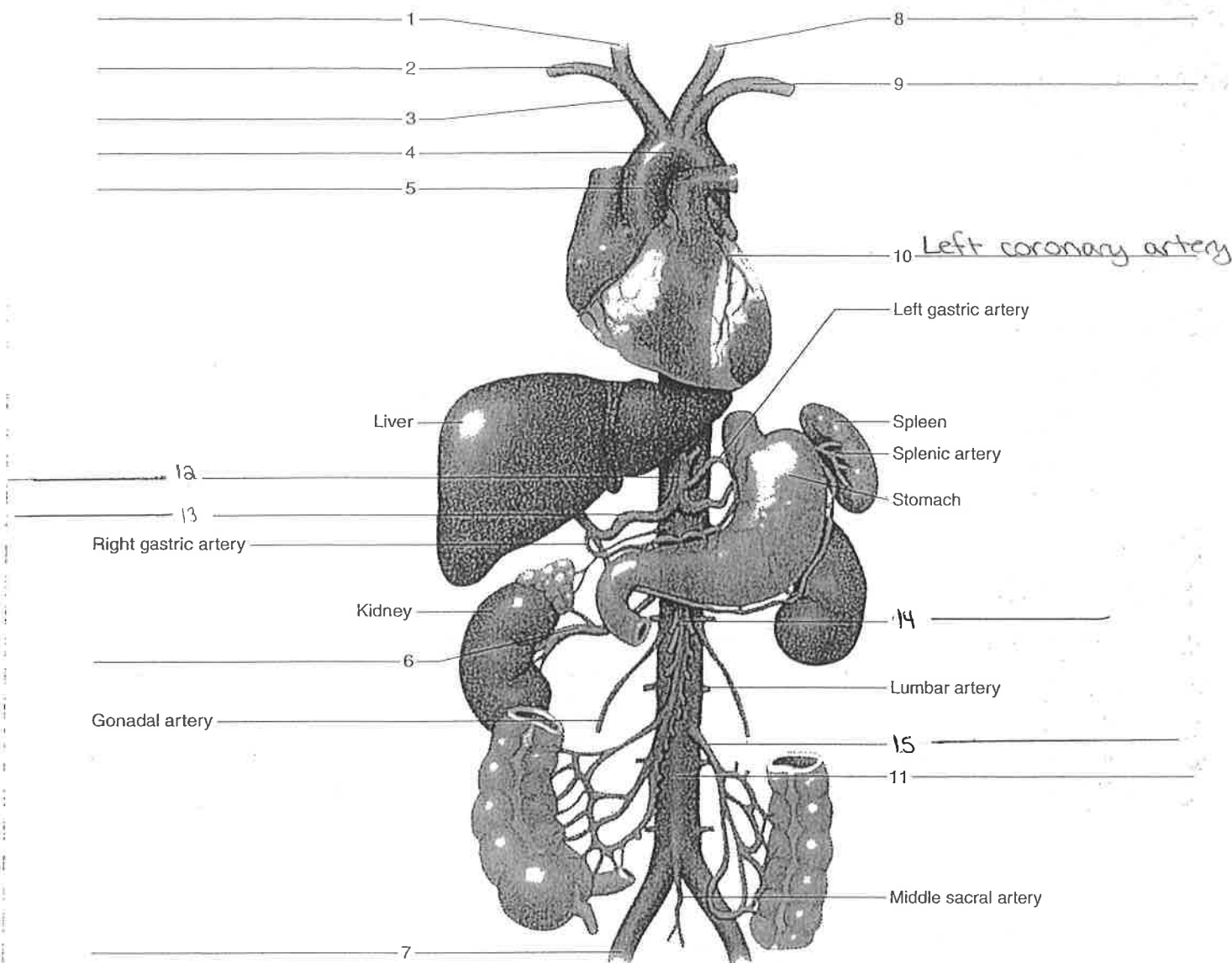


Figure 40.2 Label the portions of the aorta and its principal branches.



arteries to shoulder and upper limb

- axillary artery
- brachial artery
- deep brachial artery
- ulnar artery
- radial artery

arteries to the thoracic and abdominal walls


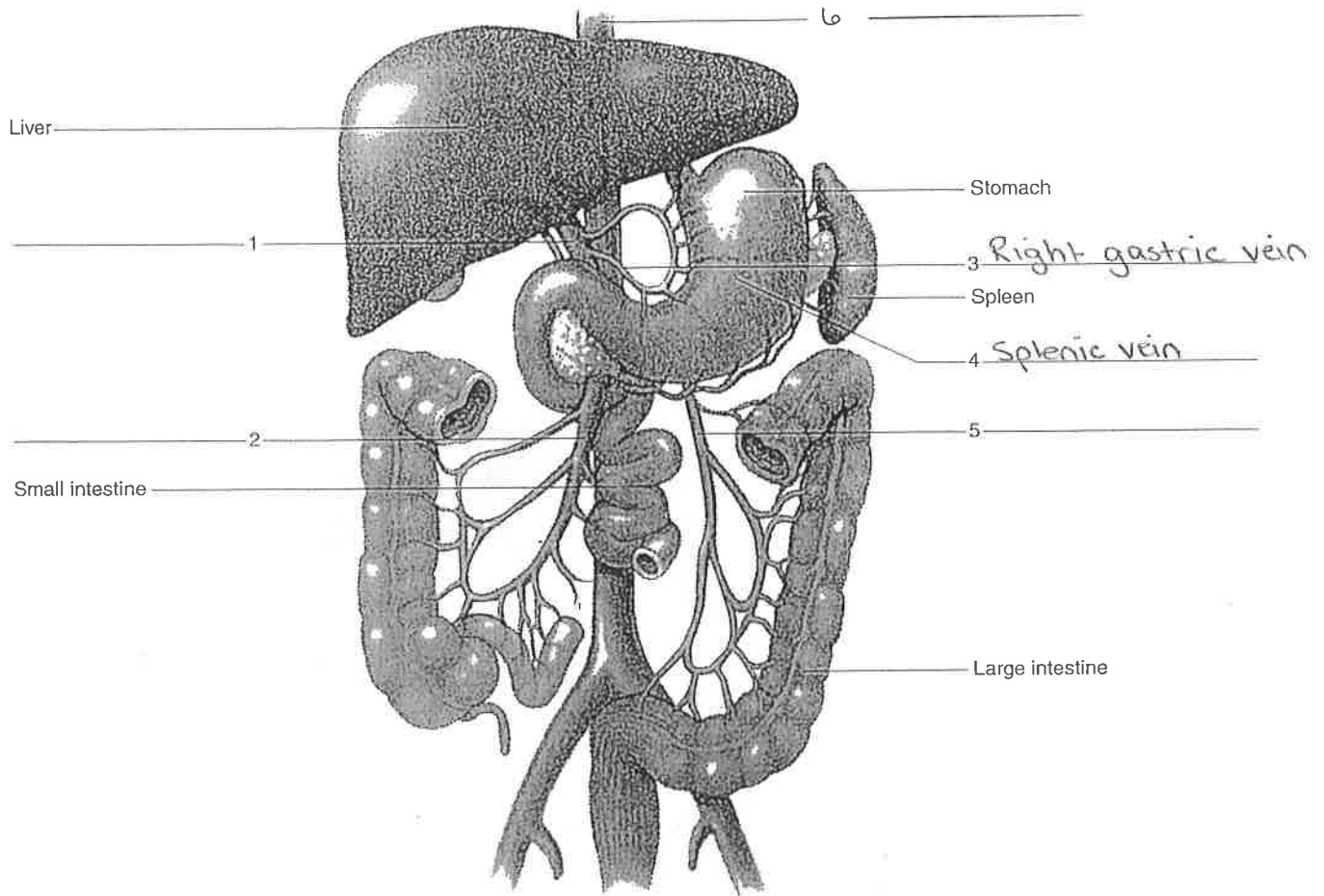
- internal thoracic artery
- anterior intercostal artery
- posterior intercostal artery

arteries to pelvis and lower limb

- common iliac artery
- internal iliac artery
- external iliac artery
- femoral artery
- popliteal artery
- anterior tibial artery
- dorsalis pedis artery (dorsal pedis artery)
- posterior tibial artery

4. Complete Parts A and B of Laboratory Report 40.

Figure 40.9 Label the veins that drain the abdominal viscera (hepatic portal system).



Web Quest

Identify the major arteries and veins, and describe their functions. Observe an animation of the exchanges in a capillary. Search these at www.mhhe.com/shieress9