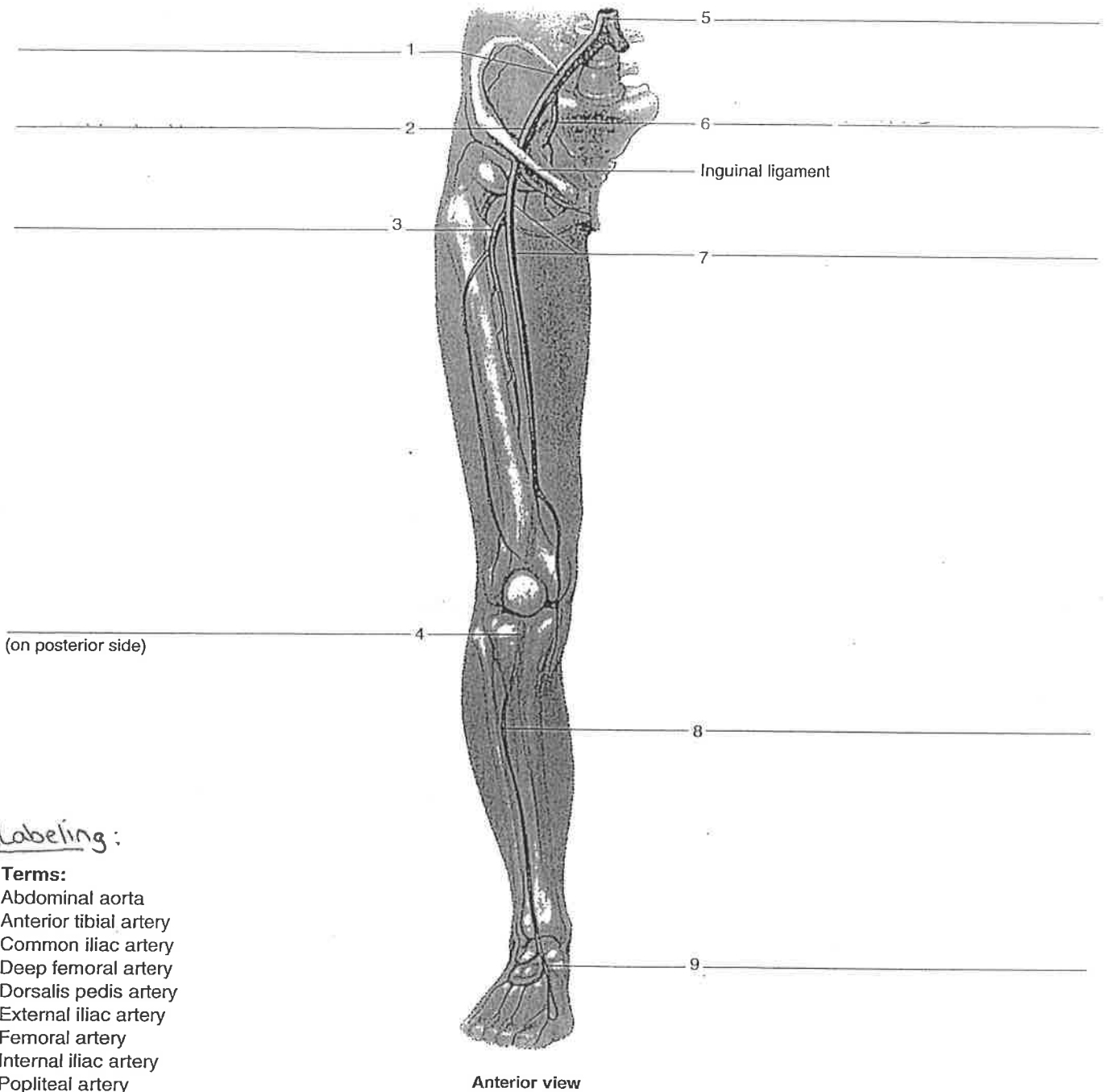


* ARTERIES *

Figure 40.5 Label the major arteries supplying the pelvis and lower limb, using the terms provided.



* Labeling:

Terms:

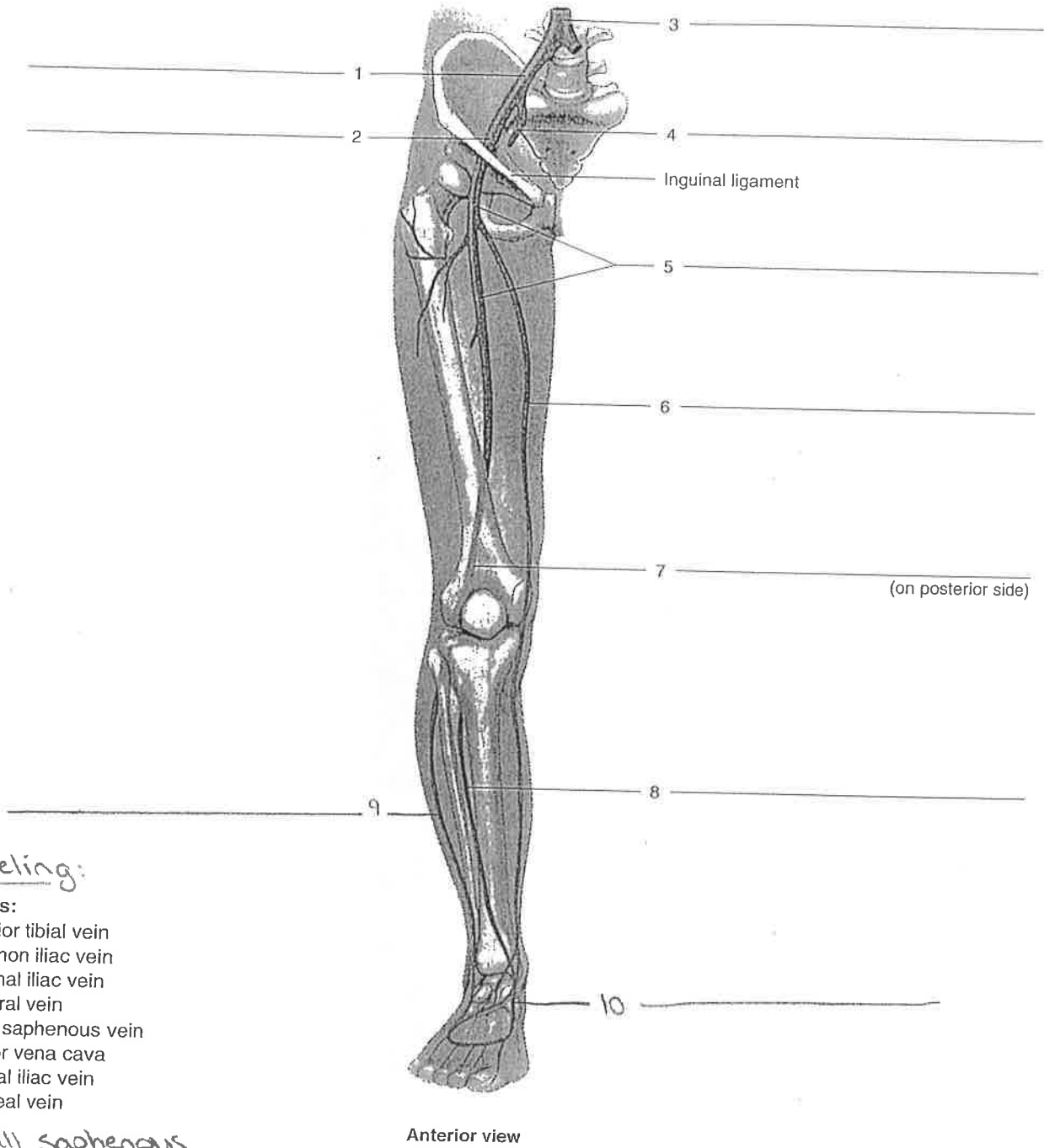
- Abdominal aorta
- Anterior tibial artery
- Common iliac artery
- Deep femoral artery
- Dorsalis pedis artery
- External iliac artery
- Femoral artery
- Internal iliac artery
- Popliteal artery

* Draw In:

- Posterior tibial artery
- Peroneal artery

* VEINS *

Figure 40.10 Label the veins of the pelvis and lower limb, using the terms provided.



*** Labeling:**

Terms:

- Anterior tibial vein
- Common iliac vein
- External iliac vein
- Femoral vein
- Great saphenous vein
- Inferior vena cava
- Internal iliac vein
- Popliteal vein

Small saphenous

Dorsalis pedis

Anterior view