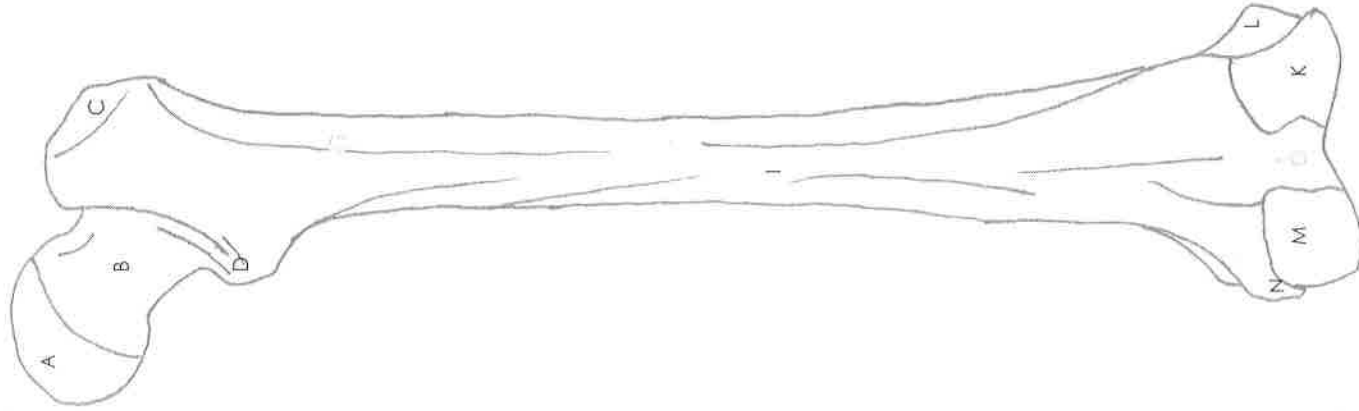



FEMUR

Anterior

Posterior



Name: _____

Date: _____ Period: _____

Answer Key

- A. Head
- B. Neck
- C. Greater trochanter
- D. Lesser trochanter

I. Shaft

- K. Lateral condyle
- L. Lateral epicondyle
- M. Medial condyle
- N. Medial epicondyle

Q. Patellar surface

KEY TO FIGURE IV-11

- 1. greater trochanter
- 2. neck

- 4. lesser trochanter
- 5. lateral epicondyle
- 6. patellar surface

- 9. medial epicondyle

KEY TO FIGURE IV-12

- 1. head
- 2. greater trochanter
- 3. neck

- 5. lesser trochanter

- 8. lateral condyle
- 9. medial condyle

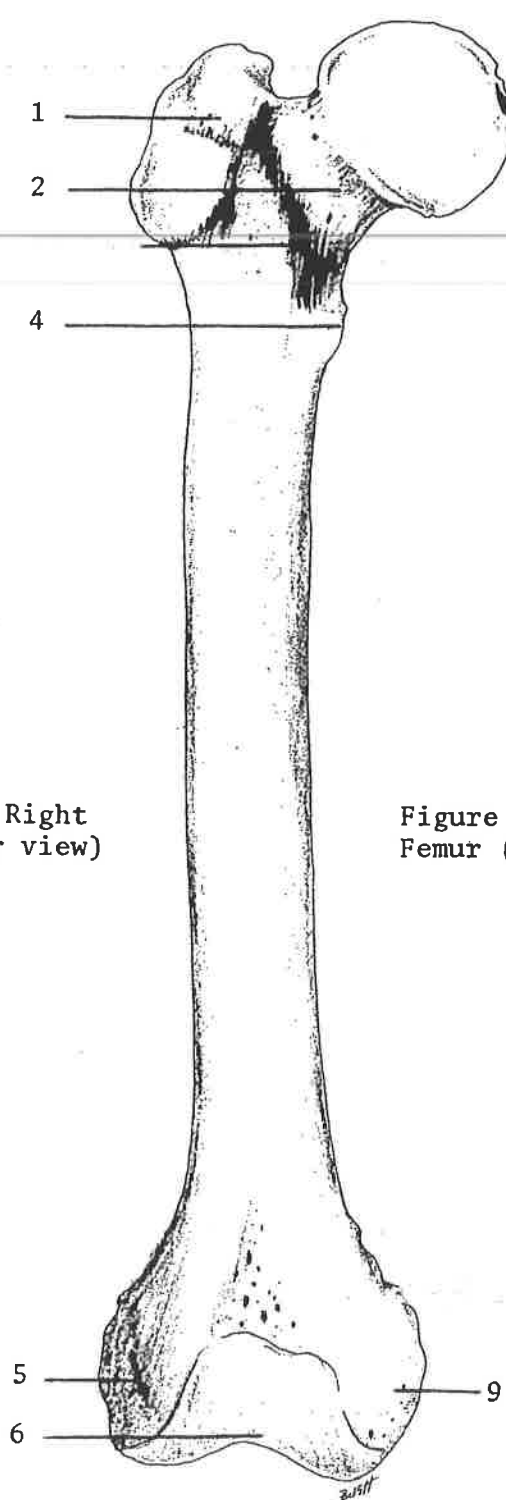


Figure IV-11: Right Femur (anterior view)

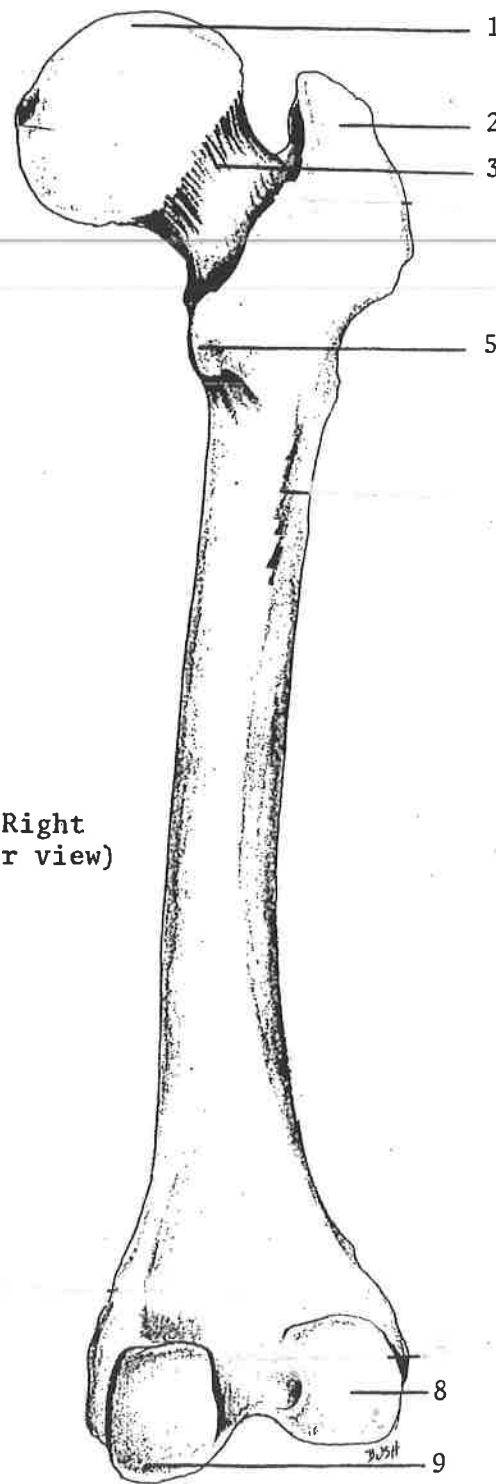




Figure IV-12: Right Femur (posterior view)

TIBIA & FIBULA

Posterior



Anterior



Name: _____
Date: _____ Period: _____

Answer Key

- A. Lateral condyle
- B. Medial condyle
- C. Fibula head
- D. Tibial tuberosity
- G. Lateral malleolus
- H. Medial malleolus
- K. Tibia body
- L. Fibula body

KEY TO FIGURE IV-13

1. styloid process

2. head of fibula

3. lateral malleolus

KEY TO FIGURE IV-14

2. medial condyle

4. tibial tuberosity

3. lateral condyle

6. medial malleolus

8. fibular notch

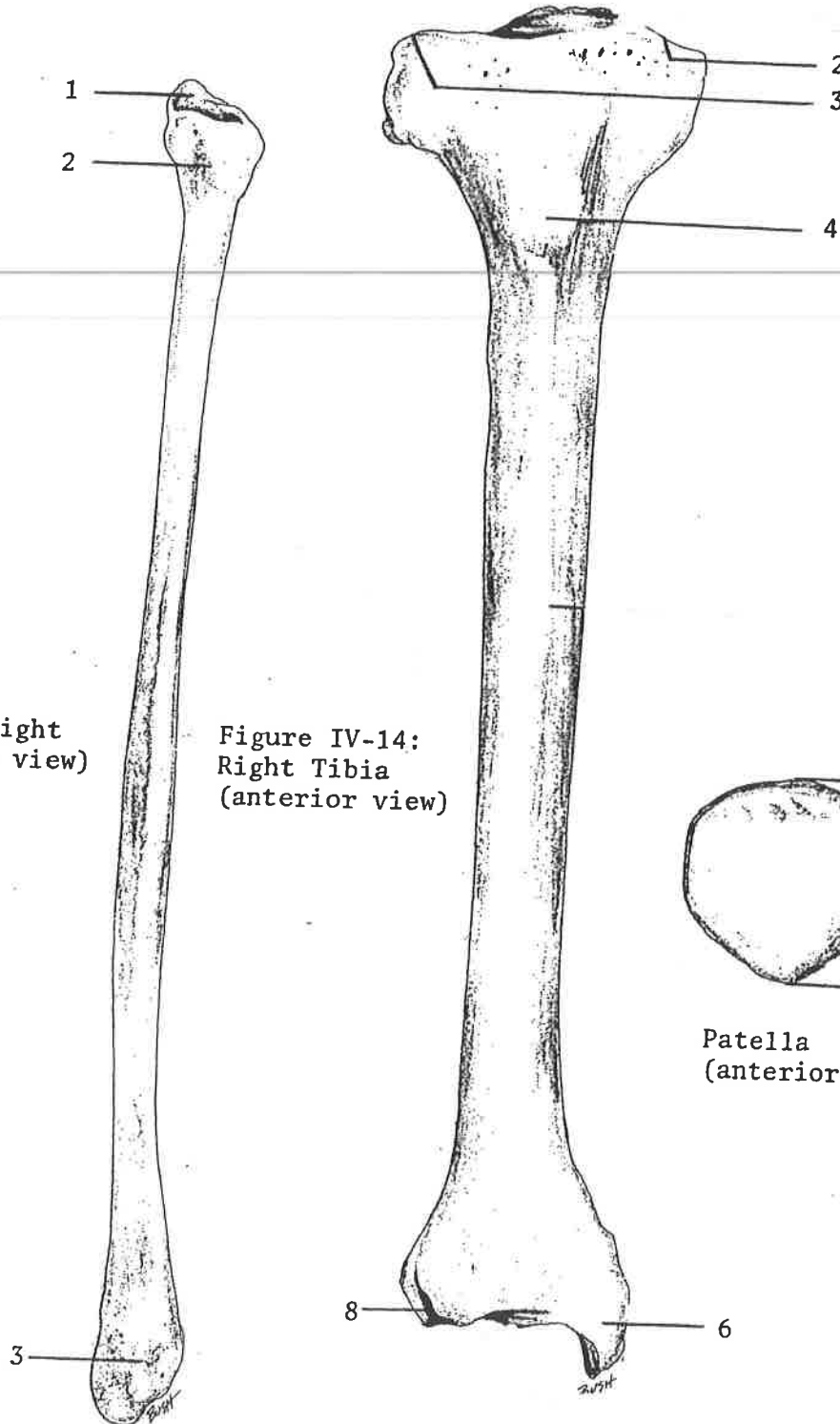
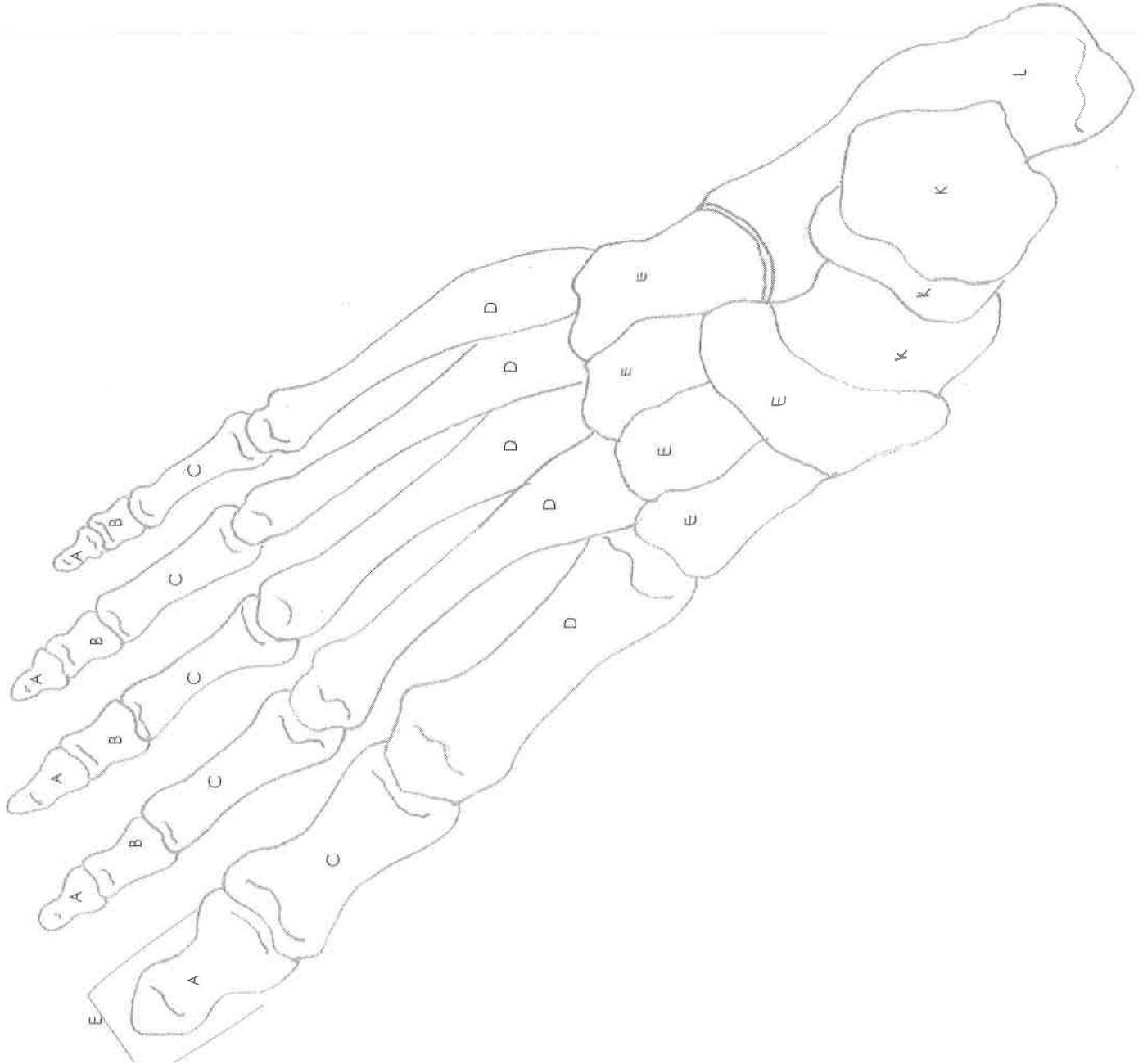


Figure IV-13: Right Fibula (anterior view)

Figure IV-14: Right Tibia (anterior view)

Superior Border (base)
Apex
Patella (anterior surface)

BONES OF THE FOOT



Name: _____
Date: _____ Period: _____

Answer Key

- A. Distal phalanges
- B. Middle phalanges
- C. Proximal phalanges
- D. Metatarsals
- E. Tarsals

- K. Talus
- L. Calcaneus

Femur, Tibia, Fibula, Foot

Letter	Name of Bone	Letter	Name of Bone
A		K	
B		L	
C		M	
D		N	
E		O	
F		P	
G		Q	
H		R	
I		S	
J		T	